

EDITOR'S NOTE



Dr Manoj Durairaj

Heart Transplant Surgeon, MS, MCh. (AIIMS, New Delhi), FACC.

Director, Marian Cardiac Centre and Research Foundation.

Program Director, Department of Heart and Lung Transplantation, Sahyadri Hospitals, Pune.

Greetings dear Colleagues!

The October 2022 issue of "The Revival" has a one-of-a-kind case report of Strongyloidosis post Lung Transplant.

The authors – Dr Srinivas Rajagopala, Dr Sameer Bhate and Professor Kumud Dhital have written an article par excellence in terms of scientific content and creative flow.

The Editorial team is grateful to the authors for sharing their findings and I'm sure our Readers will be wary from here on of this parasitic infection in their post-transplant surveillance protocols. Recipients could be potentially harbouring Strongyloides in endemic areas. This and other intestinal parasites will have to be screened more diligently. Albendazole and Ivermectin in appropriate doses should be mandatory in all recipients awaiting heart or lung transplant.

I hope our dear Readers will enjoy reading this wonderfully written article.

Happy Reading!!!

Dr Manoj Durairaj
Editor "The Revival"

SUB EDITOR



Dr Talha Meeran

MBBS, MD, FACC, Consultant Cardiologist, Dept of Advanced Cardiac Sciences and Cardiac Transplant, Sir HN Reliance Foundation Hospital, Mumbai.

Dear Colleagues,

The October issue of "The Revival" is based on an interesting and a one of a kind case report in a post lung transplant setting. It's often said that several fungal infections can masquerade as other non-fungal infections however we rarely encounter another non-fungal infection masquerading as a fungal infection. The discussion that ensues has several learning points for any individual involved in solid organ transplants in a tropical setting.

Ivermectin prophylaxis should rightly be administered to all patients awaiting transplant to prevent such life threatening post-transplant infections.

Sincerely,
Dr Talha Meeran
Sub Editor "The Revival"

PRESIDENTIAL MESSAGE



Prof. (Dr) V. Nandakumar

Director & Chief, Division of Cardio Vascular/Thoracic Surgery & Cardiac Transplantation, Metromed International Cardiac Centre, Calicut, Kerala.

Dear Colleagues,

The October issue of "The Revival" presents an interesting case report -Strongyloidiasis mimicking mucormycosis - post lung transplantation authored by Dr Srinivas Rajagopala, Dr Sameer Bhate and Dr Kumud Kumar Dhital. This is an unusual entity, but definitely a concern post organ transplantation.

Authors have discussed the possible causes for increased susceptibility for hyperinfection, diagnosis and management of this infection in post transplant patients. Such case reports bring to light potential problems faced in immunosuppressed patients and hence have a high educative value.

Best wishes,
Prof. (Dr) V. Nandakumar
President

Please call or write to us:
Call: 9822322072, 9167048815,
manojdurairaj@hotmail.com,
talha.meeran@gmail.com

Link for membership,
<http://www.sfht.org/application.html>

Special thanks to Dr Srinivas Rajagopala, Dr Sameer S Bhate and Dr Kumud Kumar Dhital for authoring this month's article.

Designed by Maithili Kulkarni



SfHFT Annual Conference 2023

Society for Heart Failure and Transplantation

**Block
your Dates**
2023
MARCH
10, 11 & 12

Venue :
Radisson Blu Temple Bay,
Mamallapuram

Conference Secretariat :

No.4-A, Dr. JJ Nagar, Mogappair, Chennai 600 037, Tamil Nadu, India

Phone : +91 (44) 2656 1801 / 2656 5991 ♦ Fax: +91 (44) 2656 5859

Email : secretariat@sfhft2023.org ♦ Website: sfhft2023.org

CASE REPORT

STRONGYLOIDIASIS MIMICKING MUCORMYCOSIS POST-LUNG TRANSPLANTATION

¹@ Dr Srinivas Rajagopala MD, DM (Pul & Crit Care Medicine)

²^ Dr Sameer Bhate MCh, DNB (CTVS), DNB (Gen Surg), MNAMS, FIACS

³@ Prof Kumud Kumar Dhital BSc ,BM.BCh ,FRCS (Eng) ,FRCS-CTh (UK) ,PhD,FRACS

^{1,2} Senior Consultant, ³ Program Director

[©]Department of Heart & Lung Transplant, Kauvery Hospitals, Alwarpet, Chennai, India-600018

[^] Head Department of Adult Cardiothoracic & Vascular Surgery, Amrita Hospital, Mata Amritanandamayi Marg, Sector 88, Faridabad, Haryana, India-121002

Corresponding author

Dr Srinivas Rajagopala

Senior Consultant, Pulmonary Medicine, Director -Transplant Pulmonology & Lung Failure Unit
Kauvery Group of Hospitals, 81, TTK Road Junction, Alwarpet, Chennai, Tamilnadu, India-600018

Tel: 91- 078248 68600, E-mail: visitsrinivasan@gmail.com

Funding sources: None

Conflicts of interest: None

All authors had access to the data and a role in writing the manuscript

Article type: Strongyloidiasis

Running Head: Non-resolving pneumonia post-LT

Key Words: Lung transplantation, strongyloidiasis, non-resolving pneumonia



Dr Srinivas Rajagopala

MD, DM (Pul & Crit Care Medicine), Lung Transplant Fellowship (Toronto)

Director -Transplant Pulmonology & Lung Failure Unit Kauvery Group of Hospitals, Alwarpet, Chennai, Tamilnadu, India

Dr Srinivas Rajagopala provides comprehensive care for advanced lung diseases, with a focus on rehabilitation and lung transplantation. He has more than 19 years of experience in Pulmonology, Intensive Care, Epidemiology & Statistics and Transplant Pulmonology from several reputed teaching institutes Nationally and Internationally such as PGIMER Chandigarh, JIPMER Puducherry, Royal Adelaide Hospital Australia, McMaster University Hamilton and Toronto General Hospital, Canada.

Dr Srinivas Rajagopala is nationally well known for his interest in evidence-based management of lung diseases. His niche interests include Interstitial lung diseases and on Indian data on wait-list mortality, with an aim to reduce the same. He has authored various papers in renowned national and international medical journals and is a reviewer for several national and international journals. Currently, he is actively involved in ongoing research developments in Lung Transplantation. He is involved in reviewing outcomes of Long-term CLAD-free survivors post-Lung Transplantation of the Toronto Lung Transplantation program with Dr Stephen Juvet and Oscillometry to predict baseline allograft dysfunction with Dr Chow Chung-Wai.



Dr Sameer S Bhate

MD, DM MBBS, MCh (Cardiovascular Thoracic Surgery), DNB (General Surgery), FIACS, MNAMS
Head, Department of CVTS, Amrita Hospital Faridabad

Dr Sameer Bhate has been a proficient and dedicated Cardiothoracic Surgeon with more than 20 years of experience in treating advanced cardiac conditions while performing more than 3000 Cardiac Surgeries. He pursued MCh in Cardiovascular Thoracic Surgery from B J Medical College, Pune and thereafter received his training in Adult, Pediatric and Heart and Lung Transplant Surgery in Australia for over 9 years at various Institutions under world renowned Cardiac Surgeons.

After coming back to India, in addition to routine Cardiac Surgery, he also pursued Complex Cardiac Surgeries like Redo Cardiac Surgeries and Aortic Surgeries. He has one of the largest series of Redo Valve Surgeries in India. His keen interest in research reinforced him to have publications in various peer-reviewed medical journals and has presented various papers in Medical Conferences and workshops. He has been instrumental in setting up three Cardiac Surgery Centers in North India and two Heart and Lung Transplant programs, along with Prof Kumud Dhital in Hyderabad and Bangalore respectively.



Dr Kumud Kumar Dhital

BSc BMBCh(Oxon) FRCS(Eng) FRCS_CTh(UK) PhD FRACS

Director CTS and Heart & Lung Transplantation, QRG-Marengo Hospital, Faridabad, Haryana

Director- Heart & Lung Transplantation, Kauvery Hospitals, Chennai, Tamil Nadu

Graduate in Medicine from Oxford University, Dr Dhital obtained his Cardiothoracic Surgical training at Guy's & St Thomas Hospitals in London with Fellowships at the John Radcliffe Hospital in Oxford and Specialist Transplant Fellowship at Papworth Hospital, Cambridge, UK.

He has practiced at Senior Consultant level with academic positions in the UK (Papworth Hospital, Cambridge), Italy University of Pittsburgh (UPMC at IsMett, Palermo), Australia (St Vincents's Hospital, Sydney and The Alfred Hospital, Melbourne) and more recently in India since 2020.

Dr Dhital is globally renowned for being the surgical pioneer of DCD heart transplantation from distantly procured organs with the use of machine perfusion to reanimate, preserve and transport the donor heart that was first carried out in Sydney in 2014. Dr Dhital also has significant experience with machine perfusion of donor lungs. He provides a comprehensive cardiac and thoracic practice including pulmonary endarterectomy for CTEPH.

CASE REPORT

A 34-year-old male presented with new onset cough and exertional breathlessness of a week's duration. There was no associated fever, rash, abdominal pain, bleeding or diarrhoea. He had undergone ABO-matched bilateral lung transplantation for advanced silicosis and respiratory failure seven months prior to the current presentation. He was vaccinated for Hepatitis B, Pneumococcus, influenza, COVID-19, diphtheria, pertussis, tetanus, typhoid and meningococcus prior to his transplantation. He had also completed one dose of albendazole 400 mg and one of his two doses of ivermectin 200 µg/kg prior to transplant; the second dose was administered two weeks later post-transplant because a donor became available in the interim. His immediate post-transplant course was uneventful, and he was discharged by the tenth day post-transplant. His virtual and actual cross-match were negative at transplantation but he had a 10/14 allele mismatch with his donor on high-resolution HLA testing. His CMV risk status was intermediate with both the recipient and donor being positive for CMV IgG (D+/R+). He was initially managed with high-intensity immunosuppression (Tacrolimus trough target 12-15 ng/mL by ECLIA, Mycophenolate and steroids) and prophylaxis for mould, pneumocystis and CMV. Voriconazole was briefly held for a fortnight for cholestasis at four weeks post-discharge, and his course was subsequently complicated by Aspergillus tracheobronchitis and airway ischemia at eight weeks post-transplantation. Aspergillosis was managed conservatively with inhaled amphotericin desoxycholate and rechallenged with voriconazole; ischemia was managed by bronchoscopy and airway toileting weekly on an ambulatory basis. There was significant resolution in bronchoscopy findings with 30% stenosis of the right anastomoses and no recurrence of cholestasis on follow-up. Surveillance transbronchial lung biopsies at three and six months were A0Bx by ISHLT grading (for acute cellular rejection) and there were no demonstrable donor-specific antibodies by Luminex testing; immunosuppression intensity was reduced. Voriconazole dosed to a trough of 1-2 µg/mL and Co-trimoxazole were continued and valganciclovir prophylaxis was discontinued at six months with CMV monitoring.

During the current presentation, evaluation showed a right loculated pneumothorax and left lingular consolidation (Figure 1); computed tomography (CT, Figure 1 right) showed a "Reverse Halo" sign, raising concern for breakthrough Mucormycosis and anastomotic complications.

Bronchoscopy showed 70% stenosis of the right anastomoses without significant dehiscence; the distal right-side and left-side was normal. Bronchoalveolar lavage fluid (BALF) from the left lingula showed *Klebsiella pneumoniae* (resistant to Meropenem/Colistin/aztreonam; NDM by CarbR assay), negative for M tuberculosis by Xpert MTB/RIF and acid-fast

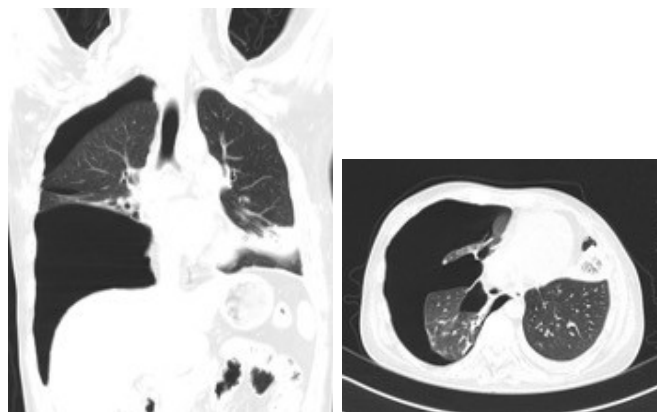


Fig 1: Composite image showing coronal reconstruction of the computed tomography (CT, left) of the chest at seven months showing right loculated pneumothorax and left lingular consolidation. Right anastomosis was intact with no evidence of extraluminal air on CT. CT chest (right) showed ground glass opacity surrounded by a dense band of peripheral consolidation, "the reverse Halo" sign in the left lingular lobe, raising concern for invasive fungal infection

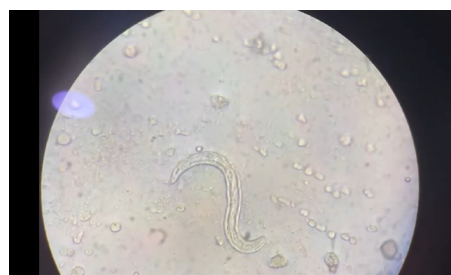

Fig 2: Wet mount of the bronchoalveolar lavage fluid showing rhabditiform larva that were motile, consistent with strongyloidiasis

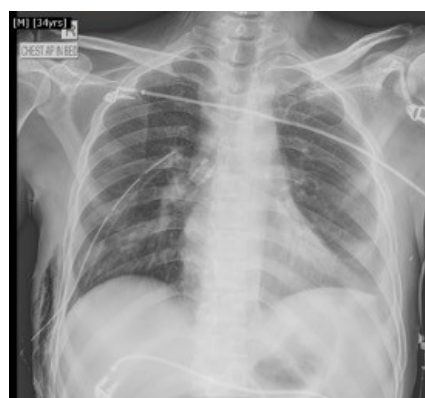

Fig 3: Chest radiograph showing complete re-expansion of the right lung and partial improvement in lingular consolidation with antibiotics and ivermectin by seven days

staining; fungal smears, BALF galactomannan and pan-fungal DNA polymerase chain reaction (PCR) were also negative. BALF wet mount unexpectedly showed rhabditiform larva consistent with strongyloidiasis (Figure 2). A diagnosis of breakthrough Strongyloidiasis and drug-resistant *Klebsiella pneumoniae* was made.

He underwent intercostal drainage on the right side (Figure 3), balloon dilatation twice to the right anastomosis, further reduction in immunosuppression intensity, and received a combination of ceftazidime-avibactam and aztreonam along with daily oral ivermectin for two weeks. *Klebsiella pneumoniae* was sensitive to Chloramphenicol on further testing and another two weeks of oral chloramphenicol and ivermectin (till two weeks after consecutive BALF-smears were negative for larvae) were administered with good clinical resolution (Figure 4, left). He subsequently needed silicone stenting at the right anastomosis for recurrent stenosis/bronchomalacia but remained asymptomatic. The stent was subsequently removed at three months follow-up with no recurrence of bronchial stenosis and stable FEV1 on follow-up (Figure 4, right).

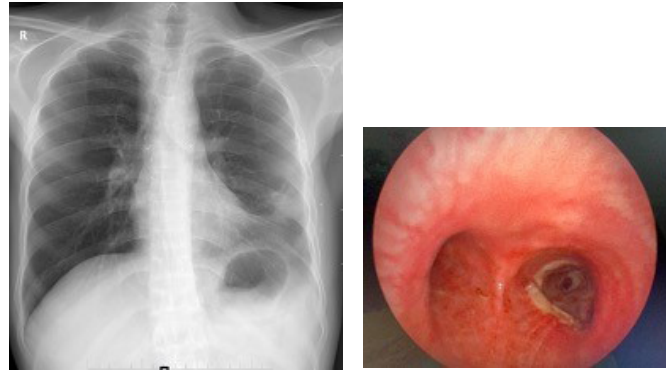


Fig 4: Composite image showing near complete radiologic resolution at six weeks (left) and normal anastomosis on the right-side post-stent removal at ten months post-lung transplantation

DISCUSSION

Strongyloides is an intestinal nematode that infects more than 10 million people worldwide and is reported mainly in the tropics¹. It is transmitted by contact with soil contaminated with human waste containing the larvae of Strongyloides. The filariform larvae of Strongyloides enters the host through the skin, migrates through the body through a variety of routes and reaches the intestinal tract to mature into the adult worm, thereby continuing its life cycle. Strongyloides have the ability to persist in the host by auto-inoculation in the gastrointestinal tract with minimal symptoms. In the immunocompromised host, the auto-inoculation syndrome can however be accelerated, causing life-threatening hyperinfection with very high mortality¹. While recognized mostly in patients on steroids, this is a particular concern post-solid organ transplantation (SOT)². Strongyloides hyperinfection most commonly results from reactivation of dormant disease. Donor-related Strongyloidiasis has been reported through intestinal, renal, renal-pancreas, and heart allografts but the timing of deceased donor donation precludes donor testing in our setting¹.

T-cell-depleting therapies, such as corticosteroids and anti-thymocyte globulin and hypogammaglobulinemia, increases susceptibility to hyperinfection. Cyclosporine, interestingly, is markedly parasitocidal against Strongyloides and the majority of cases reported post-SOT are in those treated with cyclosporine-sparing regimens¹.

In SOT, strongyloidiasis presents early within six months with vague gastrointestinal symptoms. With hyperinfection, symptoms correlate with larval migration, causing pyrexia,

gastrointestinal pain, bloody diarrhea, ileus, and lung injury with bilateral infiltrates. A purpuric rash can occur in the area of larva currens, which reflects skin invasion as the larvae migrate to reach the gastrointestinal tract through the skin².

Eosinophilia is often absent due to steroid therapy post-SOT. With disseminated disease, super-added sepsis or meningitis with gram-negative bacteria is common and must be treated.

Diagnosis of Strongyloides is made by direct identification of larvae or stool PCR testing against 18s rRNA of stool or duodenal aspirate. Diagnosis can also be made by a skin biopsy in larva currens or by sputum, bronchial aspirates, CSF, urine and peritoneal fluid in disseminated infections³. Serology has very poor sensitivity in disseminated infection. The ideal method of screening in the tropics prior to SOT is unknown. In non-endemic areas, serology is used prior to SOT to guide presumptive treatment; however, it is neither sensitive nor specific and cannot distinguish between prior or current infections and has cross-reactivity with other helminthic infections that are common in the tropics. Furthermore, serial screening to diagnose intercurrent infections may be needed in patients with longer wait-list time⁴. In endemic areas, it is common practice to presumptively treat prior to SOT due to the high prevalence and unavailability of serologic testing; breakthrough infections have not been reported. The index case is the only one reported to the best of our knowledge. Given the late occurrence, donor-derived infection is unlikely. We postulate that the patient had a significant asymptomatic intestinal load that was treated by his pre-transplant regimen and

the localized pulmonary disease rather than hyper-infection post-SOT was due to incomplete clearance of persisting low-level infestation. We are currently collecting more data on breakthrough infections with our current protocol to evaluate for alternative regimens in endemic areas.

Treatment is with ivermectin and appropriate antibiotics to treat bacterial super-infection. Albendazole also has activity

against strongyloidiasis but is inferior to ivermectin. It is imperative to reduce immunosuppression concurrently. Patients with ileus need parenteral ivermectin but this is currently unavailable in India.

CONCLUSION:

Radiologic signs are not specific and microbiologic confirmation must be sought for definitive treatment. Strongyloidiasis is a common parasitic infestation in the tropics and should be considered in the differential diagnosis of early post-transplant infections in the tropics. A universal presumptive treatment strategy prior to SOT is currently used in the tropics and breakthrough infestations are very rare but can occur.

References:

1. Roxby A.C, Gottlieb G.S and Limaye A.P. Strongyloidiasis in Transplant Patients. *Clinical Infectious Diseases* 2009; 49:1411–23
2. Mogleya C.M, Dhalaa A and Ghobrial R.M. Strongyloides stercoralis in solid organ transplantation: early diagnosis gets the worm. *Curr Opin Organ Transplant* 2017, 22:000–000
3. Hayes J and Nellore A. Management of Strongyloides in Solid Organ Transplant Recipients. *Infect Dis Clin N Am* 2018; 32: 749–763
4. Camargo J.F, Simkins. J, Anjan.S, Guerra.G, Vianna. R, Salama.S et al. Implementation of a Strongyloides screening strategy in solid organ transplant donors and recipients. *Clinical Transplantation*. 2019;33: e13497.

PRESIDENT

DR V NANDAKUMAR

Mob: 9843015888

Email: drvnandakumar@gmail.com

PRESIDENT ELECT

DR RONY MATHEW

Mob: 9846097812

Email: drromymathew@yahoo.com

VICE PRESIDENTS

DR JULIUS PUNNEN

Mob: 9980072785

Email: jpunnen@hotmail.com

DR AJITKUMAR V K

Mob: 9895153684

Email: ajitkumarvk@yahoo.com

SECRETARY

DR JABIR ABDULLAKUTTY

Mob: 9447011773

Email: drjabir@yahoo.co.in

JOINT SECRETARY

DR RAJAGOPAL S

Mob: 9747606600

Email: srajagovindam@gmail.com

TREASURER

DR PRAVEEN G PAI

Mob: 9847334434

Email: praveen.pai.g@gmail.com

PAST PRESIDENTS

DR GEEVAR ZACHARIAH

(2013-2014 and 2014-2015)

Mob: 9846066816

Email: geevarzachariah@gmail.com

DR SHIV K NAIR (2015-2016)

Mob: 9846010220

Email: Shivnairmd@gmail.com

DR K VENUGOPAL (2016-2017)

Mob: 9847005444

Email: venugopalknair@gmail.com

DR JOSE CHACKO PERIAPURAM

(2017-2018)

Mob: 9847043224

Email: joseperiapuram@hotmail.com

DR P P MOHANAN (2018-2019)

Mob: 9846076006

Email: drppmohan@yahoo.com

MEMBERS

DR C G BAHULEYAN

Mob: 9447344882

Email: bahuleyan2001@yahoo.co.uk

DR P CHANDRASEKHAR

Mob: 9443047152

Email: chanpad@gmail.com

DR COL JAMES THOMAS

Mob: 9892797060

Email: thomasdrjames@yahoo.in

DR JACOB ABRAHAM

Mob: 9847128123

Email: jacobraham1@gmail.com

DR JAYAGOPAL P B

Mob: 9847023777

Email: jaigopallakshmi@gmail.com

DR KARTHIK VASUDEVAN

Mob: 9845281450

Email: karvasudevan@gmail.com

DR C S HIREMATH

Mob: 9481119646

Email: hiremath.cs@sss.hms.org.in

DR MANOJ DURAIRAJ

Mob: 9822322072

Email: manojdurairaj@hotmail.com

DR RAJESH RAMANKUTTY

Mob: 9846005737

Email: drrajesh_mr@yahoo.com

DR V K CHOPRA

Mob: 9560898900

Email: chopravk@gmail.com

DR TALHA MEERAN

Mob: 9167048815

Email: talha.meeran@gmail.com